

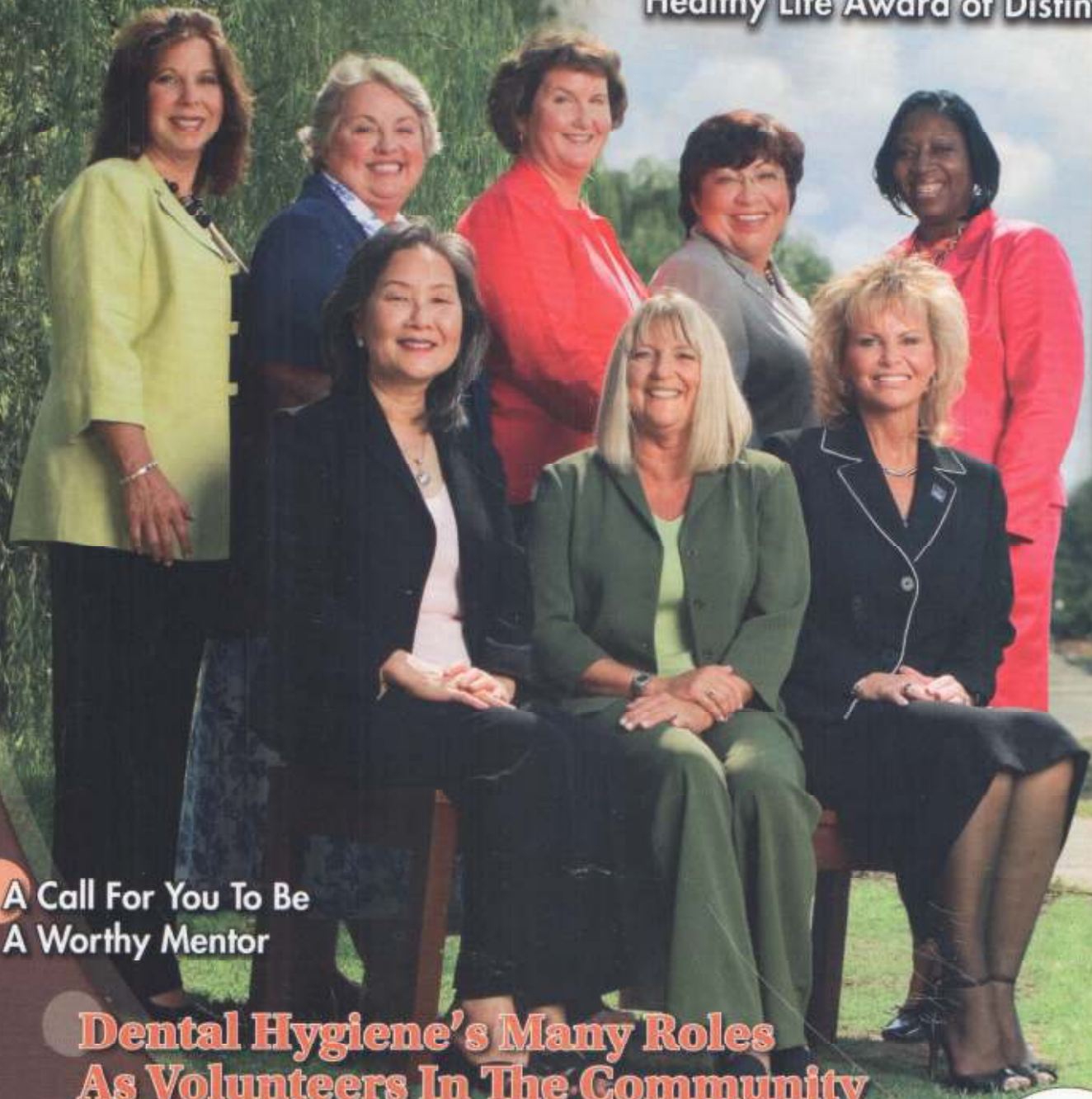
September 2007

PennWell

# RDH<sup>®</sup>

THE NATIONAL MAGAZINE FOR DENTAL HYGIENE PROFESSIONALS

## Meet the Recipients of 2007 Sunstar/RDH G.U.M. Healthy Gums, Healthy Life Award of Distinction



A Call For You To Be  
A Worthy Mentor

Dental Hygiene's Many Roles  
As Volunteers In The Community

Infection Control  
Right At Your Fingertips

Oral Cancer  
Risk and Detection:  
The Importance  
of Screening  
Technology  
4 CE Units

[www.rdhmag.com](http://www.rdhmag.com)

## IN THIS ISSUE

### FEATURES

- 16** "RDH Event"
- 34** "The Sixth Annual Healthy Gums. Healthy Life. Award of Distinction"  
*By Cathleen Terhune Alty, RDH*
- 52** "Aspire to be Worthy"  
*By Donna Brogan, RDH*
- 60** "Making the World a Better Place"  
*By Ann-Marie DePalma, RDH, MEd, FAADH*
- 68** "Against All Odds"  
*By Cindy Kleiman, CDA, RDH, BS*

### COLUMNS

- 28** From the Edge  
"Dream On"  
*By Lory Laughter, RDH, BS*
- 32** Periodontal Therapy  
"Stirring the Gumbug Pot"  
*By Lynne H. Slim, RDH, BSDH, MSDH*
- 72** Comfort Zone  
"Turning the Prevention Spotlight on Ourselves"  
*By Anne Nugent Guignon, RDH, MPH*
- 74** Staff Rx  
"Patients Who Balk At Medical Histories"  
*By Dianne D. Glasscoe, RDH, BS*

### DEPARTMENTS

- 10** Editors Note
- 12** Readers' Forum
- 18** Industry News
- 100** Continuing Education
- 157** RDH Mart
- 159** Classifieds
- 160** Rapid Response



34

**Waving Back At Award Winners**  
Meet the recipients of the 2007 Sunstar/RDH magazine G.U.M. Healthy Gums, Healthy Life Award of Distinction.



## Against All Odds

*A 46-year-old hygienist who doesn't smoke and doesn't drink has head-and-neck cancer. How can that be? Oral cancer causes nearly 7,500 deaths each year. It is as prevalent as cancers of the blood, kidneys, thyroid, and ovaries. Here's what we need to know.*

**By Cindy Kleiman, CDA, RDH, BS**

I met Sandy Boody, a fellow dental hygienist, in San Antonio, Texas. We were both consulting for Biotene/Laclede at a national oncology nursing convention. Ironically, the nurses attending the meeting on "Oral Care for Cancer Patients" could be the same RNs who would be caring for my colleague in her upcoming battle to survive head and neck cancer.

Sandy and I are both college faculty and are both experienced working with the medically compromised patient. We enjoy our times together and have many similarities, not only in our careers but in our personal lives as well. Sandy lives in the Pittsburgh area, and I live in the Phoenix area.

The story of Sandy Boody is one I've wanted to share. It is her own private journey, yet it is one that, if shared, could save a patient's life or even your own. I am grateful to be allowed to tell you this story.

Sandy Boody, CDA, RDH, MEd, graduated from the University of Pittsburgh. She spent two decades of her career as an educator at Al-

legheny Community College/Northern Area Special Purpose Schools. She has taught many courses, including head and neck anatomy, which has given her knowledge that ended up being her lifeboat. Besides teaching, treating the medically compromised patient remains her passion. Hospital dentistry and nursing home care were interests that Sandy participated in for many years during her summer teaching breaks. She also was passionate about xerostomia and oncology care, as they are so important for those undergoing both chemotherapy and radiation.

Soon, she would experience both.

### Problems, But No Answers

Two years after our meeting, Sandy experienced what seemed to be a “severe case of the flu.” That was followed for months by recurring respiratory and sinus infections. Multiple courses of antibiotics were prescribed, without any long-term success. The second, third, and fourth doctors were seen, without any additional ideas as to why the infections would not clear up. Maybe it was a chronic allergy? Maybe it was environmental? Maybe it was ... they just didn’t know. As this saga continued, more tests followed: chest X-rays, sinus films, blood work, pano/ceph films, all without an answer. Eventually Sandy requested that the ENT doctor perform an endoscopic exam to investigate her problem more thoroughly. The test was done in-office, and the result was interesting. The base of the left side of her tongue was ulcerated. This ulceration was explained to be most likely due to chronic postnasal drip and the irritation from it. No oral pain or symptoms were noted. Again, she was told this must be due to chronic allergies. Medications were tried again to control the symptoms of allergies, and Sandy was even told to “move to Arizona.”

Over the next year, she experienced chronic transient adenopathy (swollen lymph nodes) and increased exhaustion. Of course, this makes sense with chronic infection. However, Sandy began to feel worse and noticed a swollen lymph node

on the left side that didn’t go away, even when the infection cleared up for a time. This had a thicker texture than before. Again, she returned to the physician with concern about the node. This time she was told to “just go home, have dinner out with some wine, and relax.” The doctor assured her she was just fine, and that she was simply overreacting. Sandy believed a biopsy was indicated. It was explained to her that a needle biopsy was not needed, that she was overly concerned, not at risk for oral cancer, and this was just from the chronic infections and irritation. The doctor suggested a sabbatical so she could relax and unwind. “Come back in six months,” she was told. If Sandy had listened, she would probably not be alive today to share this story.

### Self-Referral and Diagnosis

How many of us provide oral cancer exams? How many of us are sure to do external exams? Luckily, Sandy felt this was always important and if a patient had a node that was unilateral and hard, that patient would be referred for a biopsy. So, in 2001, Sandy made the referral herself, even though her physician felt it was not needed.

During the first week of her suggested sabbatical, Sandy called and made an appointment at the Head and Neck Cancer Center at the University of Pittsburgh Medical Center. She requested the department chair and was scheduled within the week. Within minutes of his examination, she knew she was right to be concerned, as the ENT’s fingers froze on the left side of her neck. Two hours later, she stood in front of the screen viewing her radiographic images. It included computer tomography, CT and PET scans used to classify the stage of the disease. The ulcers on the base of the tongue were not due to postnasal drip. Sandy had cancer. She soon learned she had Stage 3–4 nonoperative squamous cell carcinoma. The primary site was the base of the tongue, plus lymph node involvement. Five-year survival rate for this type of cancer is a dismal 33 percent. It was 2001 and Sandy was 46 years old, with a husband and two daughters, ages 10 and 12.

### Treatment

This disease is one that is usually diagnosed in older men who drink and smoke. How do you treat a 46-year-old? There is little oncology protocol for treating this disease in a younger patient. Sandy decided to go with an aggressive

*Continued on page 153*

### Oral Cancer Facts

- The five-year survival rate from oral cancer has not significantly improved in the past 30 years, remaining at approximately 50 to 59 percent.
- The ratio of men to women diagnosed with oral cancer is 2:1. Over a lifetime, the ratio comes closer to 1:1 with advancing age.
- Dental clinicians can make a significant impact by conducting oral cancer screenings on a yearly basis and more frequently for those at higher risk.

nonsurgically, it's essential for us to focus on antimicrobial effects and ultimately on overall health outcomes. ●●●

### About the Author

*Lynne H. Slim, RDH, BSDH, MSDH, is a practicing hygienist/periodontal therapist who has more than 20 years' experience in both clinical and educational settings. She is also president of Perio C Dent Inc. (Perio-Centered Dentistry), a practice-management consulting firm that specializes in creating outstanding dental hygiene teams. Lynne is a member of the Speaking and Consulting Network (SCN) that was founded by Linda Miles, and has won two first-place journalism awards from ADHA. Lynne is also owner/moderator of a periodontal therapist yahoo group: <http://yabooogroups.com/group/periotherapist>. She can be contacted at [perioindent@mindspring.com](mailto:perioindent@mindspring.com).*

## F | Kleiman

*continued from page 70*

treatment. She had concurrent, debilitating chemotherapy and radiation therapy for seven weeks. That was followed by a treatment called brachytherapy (insertion of radioactive implants). This was done as an inpatient. Sandy had both a feeding tube and a tracheostomy tube inserted. Knowing oral care protocol for oncology patients so well herself, Sandy educated the RNs who would be caring for her. Prior to hospitalization, she established her own oral care plan and instructed the nurses who would be caring for her exactly how she wanted her care provided. Sandy was the only woman on her floor, the only nonsmoker, and the only one under 50 years old. She believes the hospital nurses, who were young women themselves, were not only caring for her, but rooting for her at the same time.

Sandy's life was turned upside down for 18 months, but she made it through the nightmare. She credits her own knowledge and the gifted UPMC staff for saving her life. Excellent nutrition and oral care were very important to her, and throughout her cancer treatment she did not develop any opportunistic infections, which is highly unusual.

### A New Look At Oral Cancer Exams

There are new and emerging oral cancer screening technologies. These new products are a valuable tool for cancer screening, but they do not replace a palpation exam, any more than a mammogram can take the place of a manual breast exam. In Sandy's case, the cancer was so far back in the throat that it could not be visualized or palpated. However, if Sandy had not done her own extraoral exam, the node may never have been addressed. How many of us are doing oral cancer exams? How many of us look very carefully for signs

### References

1. Hanes PJ, Purvis JP. Local anti-infective therapy: pharmacological agents. A systematic review. *Ann Periodontol* 2003; 8(1): 80.
2. Slots J. Selection of antimicrobial agents in periodontal therapy. *J Periodont Res* 2002; 37: 389-398.
3. Derdipoulou FV, Nonhoff J, Neumann K, et al. Microbiological findings after periodontal therapy using currettes, Er:YAG laser, sonic and ultrasonic scalers. *J Clin Periodontol* 2007; 34: 588-598.
4. Socransky SS, Haffajee AD. Periodontal microbial ecology. *Periodontology* 2000 2005; 38: 135-187.

of cancer in a 46-year-old woman who doesn't smoke? I will admit that my eyes would not have been as focused on someone like Sandy as they would be on an elderly male with risk factors. But my perception has now changed. I will now place the same focus on the old and the young, the smoker and the nonsmoker. Providing an external head and neck exam will forever have a great importance in total patient care.

### Today

It is now six years later and thankfully Sandy is still with us and doing very well. She now partners at UPMC as a patient advocate, assists with support groups, and, as always, teaches the importance of oral care for the oncology patient.

This year, once again, Sandy and I stand together at the Biotene booth at the National Oncology Convention. We continue to teach the nurses the importance of oral care for their patients. What a pleasure it is to be working together after all she has endured. She is still a wonderful hygiene instructor, an oncology educator, and is grateful to be a cancer survivor. Her knowledge was her power! ●●●

### About the Authors



*Sandy Boody, CDA, RDH, MEd, is a speaker on xerostomia, oncology, and hands-on courses to provide intra- and extraoral exams. She includes her personal story. Sandy can be reached at [BoodyS@aol.com](mailto:BoodyS@aol.com) or at (412) 576-7402.*

*Cindy Kleiman, CDA, RDH, BS, is a speaker on care of the disabled patient and on medical emergencies in the dental office. She can be reached at [JCKleiman@cox.net](mailto:JCKleiman@cox.net) or at (480) 342-9655.*

